MS: Is it One Disease?

MH Barnett[1,2], JDE Parratt[1], JD Pollard[1,2], JW Prineas[1,3]

[1]Institute of Clinical Neurosciences, University of Sydney, New South Wales, Australia; [2]Brain and Mind Research Institute, University of Sydney, New South Wales, Australia; [3]Departments of Neuroscience and Pathology, University of Medicine and Dentistry of New Jersey, New Jersey Medical School, Newark, New Jersey, USA

Summary

Neuropathological studies of early multiple sclerosis (MS) tissue have shaped prevailing views of the pathogenesis of the disease. The hallmark of the acute MS lesion, inflammatory demyelination, has been largely accepted as evidence of a macrophage-mediated attack on normal myelin, driven by perivascular and parenchymal autoreactive CD4+ Th1 cells primed in the periphery by an unknown self or foreign antigen(s). Predicated largely upon comparisons with experimental allergic encephalomyelitis, this paradigm has, in recent years, been recognized as a simplification of the events that constitute and perhaps presage lesion formation in the human disease; and the importance of the innate immune cells of the central nervous system, humoral factors, cytotoxic CD8+ T-cells and regulatory T-cells has been emphasized. An influential series of publications by one group, based on histopathological examination of actively demyelinating lesions in selected autopsy and biopsy MS tissue, defined four early lesion subtypes. In a given individual, these subtypes were reported to be mutually exclusive, suggesting that disparate pathogenetic pathways separate patients with clinically indistinguishable syndromes. This schema, which has considerable therapeutic implications, has not been independently verified and has recently been questioned by the finding of a uniform *pre*-phagocytic pathology and overlap of lesion subtypes in individual patients with typical relapsing and remitting disease. The latter findings would suggest that the heterogeneous features observed in active MS lesions sampled at different time-points are a reflection of the evolution of a single pathophysiological process, perhaps modified in part by genetic factors in individual cases.

KEY WORDS:

Multiple sclerosis; Pathogenesis; Heterogeneity; Homogeneity; Oligodendrocyte

Introduction

Multiple sclerosis (MS) has been recognized as a disease entity for over 150 years, having first been described pathologically as a 'peculiar diseased state of the spinal cord and pons Varolii' by Carswell in 1838.[1] In its typical relapsing and remitting form, MS is a characteristic clinical syndrome that, despite protean symptoms reflecting varying sites of the central nervous system (CNS) affected by inflammatory demyelination, is rarely misdiagnosed by the experienced neurologist. The advent of magnetic resonance imaging (MRI), and its incorporation into current criteria for the diagnosis of MS, also permits an accurate diagnosis in a majority of patients with a first clinical demyelinating event.[2] Although largely supplanted by MRI as a diagnostic tool, evidence of intrathecal synthesis of oligoclonal immunoglobulin is a characteristic and stable laboratory finding, present in over 90% of all MS patients, that is unaffected by immunomodulatory, immunosuppressive or other therapies.[3,4]

Whilst the relatively stereotyped clinical, imaging and laboratory features of relapsing MS suggest a uniform pathophysiology, there is a substantial variation in disease severity and response to immunomodulatory therapies; and a number of less classic variants are recognized, including primary progressive MS (PPMS), fulminant MS (Marburg variant) and the neuropathological entity, Balo's concentric sclerosis. Neuromyelitis optica (NMO), also traditionally considered an MS variant, is differentiated by: unique

Key Points

- *Relapsing MS presents with an array of relatively stereotyped clinical, radiological and laboratory features*
- *Lesional heterogeneity is present both within and between individuals with MS, and likely reflects the evolution of a single pathophysiological process rather than heterogenous disease aetiologies*
- *Inflammatory demyelination, the pathological hallmark of active MS, is a 'late' event in the newly forming lesion, and is preceded by a uniform pre-phagocytic pathology that suggests early oligodendrocyte injury or loss*
- *Traditional animal models of MS inadequately reflect the early neuropathological features of the disease*
- *Therapies that target only the recruitment of a systemic immune response are likely to be partially effective, and neuroprotective strategies are also required*

imaging, cerebrospinal fluid (CSF) findings and neuropathology; a relatively strong association with autoimmune disease; and a favourable response to plasma exchange. The recent discovery of antibodies to aquaporin-4, a protein enriched in glial limiting membranes, in sera from most patients with relapsing NMO and few with conventional MS, has served to further distinguish the two entities.[5,6]

The delineation of significantly different disease pathomechanisms amongst MS patients with conventional disease and overlapping clinical phenotypes would have important therapeutic implications, particularly for the development of novel, targeted treatments. In the early relapsing phase of the disease, neuropathological examination of MS tissue shows a spectrum of lesion pathologies. While active lesions are defined pathologically by the presence of partially myelinated axons in tissue infiltrated by numerous myelin-laden macrophages,[7] the morphological features of an individual plaque are often complex, and may additionally comprise zones of oligodendrocyte apoptosis or loss, myelin pallor or vacuolation, normal or aberrant remyelination, microglial activation and reactive astrocytosis. Both disease duration, measured in months to years, and lesion stage, measured in minutes to days, may affect the complexity and therefore interpretation of a lesion that has necessarily been sampled at a specific point in time. Genetic, and possibly environmental, factors are also likely to modulate the development of MS lesions in a given individual. In this review, the nature of acute lesion heterogeneity, and its implications for the pathogenesis and treatment of conventional relapsing and remitting MS, will be explored.

The Conventional MS Paradigm: Th1-lymphocyte-mediated Autoimmunity

T-lymphocytes are invariably detected within active MS lesions, both within perivascular cuffs and in lesser numbers infiltrating the parenchyma. However, the dominant cell type in such lesions is the myelin-laden macrophage, which derives predominantly from the local microglial population and outnumbers lymphocytes by at least 10:1.[8,9] Consistent with these neuropathological findings, macrophage-mediated destruction of normal CNS myelin has been proposed as the chief effector mechanism in MS. In this paradigm, loss of self-tolerance to an undetermined myelin or myelin-like antigen in the periphery drives the production of a Th1 cell clone capable of infiltrating the CNS and initiating selective cytokine- or macrophage-mediated myelin injury. Indirect support for such a process in MS includes the presence of Th1-type cytokines in the CSF of patients with active disease;[10] a pattern of chemokine receptor expression in circulating and lesion-derived T-cells compatible with a Th-1 driven process;[11,12] and immunopathological similarities with experimental allergic encephalomyelitis (EAE), an animal model in which disease is induced by active immunization with myelin proteins or by adoptive transfer of autoreactive Th1 cells.

This conventional paradigm has, in recent years, been acknowledged as a simplification of the pathogenic cascade which culminates in myelin destruction in the active MS lesion; and the role of the humoral immune system has been re-emphasized. Polar capping of immunoglobulin G (IgG) on macrophages engaged in active myelin phagocytosis;[13] the presence of large numbers of plasma cells in subacute plaques; the identification of immunoglobulin and complement products on degenerating myelin sheaths in acute

lesions;[14,15] and, most recently, evidence of dramatic clinical and radiological efficacy of the monoclonal anti-CD20 antibody, rituximab, in relapsing MS[16] support the notion that humoral factors play an important role in the immunogenesis of the disease. There is also growing scepticism that T-lymphocyte-mediated EAE constitutes a valid animal model for furthering the understanding of MS pathogenesis: whilst macrophage and lymphocyte infiltration characterize the lesions of both conditions, the inflammatory response in classical EAE is largely restricted to the subpial and perivascular regions, and the confluent zones of demyelination that typify MS are conspicuously absent. EAE models in which there is synergy between T- and B-cell responses, such as active myelin oligodendrocyte glycoprotein (MOG)-peptide EAE in the rat or marmoset, more faithfully, but still inadequately, reproduce the spectrum of pathological changes described in MS.[17]

Immunopathological interrogation of the active MS lesion discloses other features that cast doubt on the prevailing view of MS as a purely CD4+ Th1-cell-directed, macrophage-mediated process. Inflammatory cuffs are frequently observed in normal white matter contiguous with, or distant from, MS plaques of all ages; conversely, lymphocytes may be absent in some zones of early MS lesions with extensive demyelination;[7,18] and, contrary to the findings in EAE, major histocompatibility complex (MHC) Class I-restricted, clonally expanded CD8+ T-cells comprise the bulk of the lymphocytic infiltrate in MS.[19,20] CD8+ T-cells are concentrated in the recently demyelinated core of active MS lesions, appear in small clusters, and express granzyme B in their cytotoxic granules, features that suggest an antigen-driven, cytotoxic process (unpublished data). Finally, a constant, but often overlooked, feature of the active MS lesion is a variable, but often dramatic reduction in the number of oligodendrocytes,[7] whose extended plasma membranes constitute the myelin sheath. Consistent with recent pathological studies of newly forming MS lesions, in which widespread oligodendrocyte death was identified in the absence of immediate phagocytic activity or lymphocytic infiltration,[18] these features suggest that a *pre*-phagocytic insult to the oligodendrocyte/myelin complex may underpin macrophage activity and the subsequent recruitment of a systemic immune response.

The paradigm of Th1-lymphocyte-mediated autoimmunity is therefore at best a simplification of pathophysiological events that take place in the newly forming MS plaque. The neuropathological interpretation of an individual active lesion is further complicated by the superimposition of inflammatory activity on previously demyelinated or remyelinated tissue, a phenomenon that increases with disease duration and in part may explain the prevalence of failed remyelination in longstanding, secondary progressive disease.

Pathological Heterogeneity of MS Lesions: Different Pathomechanisms in Different Patients?

In an attempt to further dissect the pathogenetic events that take place in the active MS lesion, Lucchinetti *et al.* examined a large series of plaques from autopsy (n=32) and biopsy (n=51) cases and defined two distinct and mutually exclusive pathological patterns or subtypes among 80% of the included cases.[14,21] In the majority of these (Pattern 2) cases, active lesions were typically perivenous in location, characterized by the precipitation of activated complement and IgG on degenerating myelin sheaths and associated with the presence of remyelinating shadow plaques elsewhere in the CNS. By contrast, Pattern 3 lesions had ill-defined borders, were not centred on vessels, lacked IgG and complement deposition and in 8/22 cases exhibited concentric bands of demyelinated and myelinated tissue at the lesion edge. Variable oligodendrocyte apoptosis was observed at the active plaque edge in such cases, and remyelination was conspicuously absent. This pattern has been equated with that observed in Balo's concentric sclerosis, a form of acute MS characterized by concentric layering of damaged and preserved myelin.[22] Two further lesional patterns were recorded among the remaining 20% of cases studied: Pattern 1 lesions were morphologically indistinguishable from Pattern 2 lesions, but lacked IgG and complement deposition; and Pattern 4 lesions, seen exclusively in patients with PPMS, were distinguished by the presence of DNA condensation in periplaque oligodendrocytes. The exclusivity of specific patterns of active lesion pathology in individual cases led the authors to suggest that pathological heterogeneity reflected heterogenous disease

aetiologies in patients with indistinguishable clinical syndromes and therefore carries significant treatment implications.[23] Consistent, however, with the conventional MS paradigm, the authors have further suggested that the pathophysiological events in all four lesion types are initiated by peripherally activated T-lymphocytes; and that unknown mechanisms subsequently result in pathogenetic divergence.[24]

Lesions that conform strictly to the Pattern 3 phenotype were described in some 30% of all cases reported by Lucchinetti *et al.*[21] Many of these cases were atypical or based on biopsy data; in our experience, lack of complement activation in active lesions, or of remyelination elsewhere in individual cases, is exceptional in autopsy cases of relapsing MS. In a recent study, we identified activated complement (C3d and C9neo) on fragmenting myelin sheaths within 58/58 active lesions derived from 20 patients with relapsing MS;[25] and in the outer actively demyelinating bands of Balo-type lesions. The presence of activated complement on lesional myelin was not restricted to MS, being identified on disintegrating sheaths in diverse conditions affecting white matter, including viral and autoimmune encephalitides, NMO and ischaemic infarcts. These findings are supported by results of a study by Breij *et al.*, in which only Pattern 2 pathology could be defined in 33 actively demyelinating lesions from 22 patients drawn from a large unselected pool of MS material.[26] While frequently cited as an indication of pathogenic anti-myelin antibodies, IgG and complement immunostaining of disrupted myelin in MS lesions is therefore a non-specific feature that cannot be interpreted as evidence of a distinct pathogenesis or serve to define particular variants of the disease.

'Partial' Balo lesions, comprising small regions or bands of preserved/demyelinated tissue, are quite common in acute MS lesions that also exhibit otherwise typical Pattern 2 features, including complement deposition on degenerating myelin sheaths and pronounced remyelination in contiguous and more distant tissue. In our experience, many patients with typical relapsing and remitting disease exhibit this combination of pathological changes early in the disease.[18,25] Oligodendrocyte pyknosis and apoptosis, features observed in Pattern 3 pathology,[21] are present in evolving lesions derived from patients whose brains are examined shortly after or during an exacerbation of MS. Such *pre*-phagocytic lesions, and nearby active lesions derived from the same patients, also exhibit a spectrum of pathological changes, including complement deposition on lesional myelin, in individual cases; and remyelinating shadow plaques, which were notably absent in the Pattern 3 cases described by Lucchinetti *et al.*,[21] are frequently observed in such cases. The sampling of evolving active lesions at specific time-points, and the frequent superimposition of active and established lesion pathologies, is therefore a more likely explanation of pathological heterogeneity than dichotomous, or indeed quadrichotomous, pathogenic pathways among patients with typical relapsing MS.

Oligodendrocyte Death Underpins the Pathology of Evolving MS Lesions

A variable and unexplained reduction in the number of oligodendrocytes is present in most active MS lesions that arise *de novo* in previously unaffected white matter. Within weeks of onset of lesion-associated symptoms, a brisk regenerative response results in the appearance of oligodendrocyte precursors, chains of proliferating CNPase positive oligodendrocytes and thin remyelinating sheaths.[9] Oligodendrocyte loss may therefore be obscured by either florid inflammatory demyelination or striking oligodendrocyte regeneration, and has been largely overlooked as a potential pathomechanism in MS.

In a study of autopsy MS tissue, we described pathological changes that precede myelin phagocytosis in intact white matter at sites correlating with the symptoms of patients who had died during or shortly after a clinical relapse.[18] Such prephagocytic lesions were defined by: a) fields of apoptotic oligodendrocytes in the absence of a significant macrophage infiltrate; b) pronounced local microglial activation; and c) myelin pallor (on luxol fast blue-stained sections), but no overt structural myelin pathology. Parenchymal T-cells are almost absent in prephagocytic zones, are present in only modest numbers in regions of active phagocytosis and reach maximum densities in recently demyelinated, post-phagocytic tissue packed with lipid-laden macrophages (Henderson *et al.*, unpublished data). The observation of oligodendrocyte loss prior to inflammatory demyelination or lymphocyte infiltration in nascent MS lesions suggests a novel pathogenesis, namely that

macrophage activity is largely scavenger in nature and is directed toward dead, rather than normal, myelin sheaths in response to the expression of phagocytic ligands such as phosphatidylserine on their external surface. In this paradigm, tissue injury is amplified by the subsequent recruitment of a systemic Th1 immune response to the CNS by either: a) self antigen(s) unmasked during death of the oligodendrocyte/myelin complex; or b) foreign antigen that also initiates the apoptotic sequence.[27] The presence of myeloid DC-like cells expressing the chemokine receptor CCR7 in active MS lesions,[28] and of CD68+ cells containing myelin degradation products in the cervical lymph nodes of MS patients,[29,30] indirectly support the notion that antigen-presenting cells migrate from the evolving lesion to the cervical lymph nodes, where they can regulate the differentiation of naïve T-cells into effector and central memory T-lymphocytes that are capable of entering the CNS and amplifying tissue injury. Favourable Phase II trials of fingolimod,[32] a sphingosine-1-phosphate receptor agonist that prevents the egress of lymphocytes from secondary lymphoid organs,[33] are not inconsistent with this hypothesis.

While we have observed prephagocytic pathology in available tissue blocks from only a proportion of autopsy cases of early relapsing MS, patients rarely succumb to acute relapse in MS and rapid shifts in lesion pathology are likely to obscure transient cellular changes such as apoptosis within hours to days. Typical actively demyelinating lesions are present in contiguous white matter and elsewhere in the neuraxis in all cases exhibiting prephagocytic pathology examined to date. We therefore propose that lesion stage explains much of the pathological heterogeneity observed in newly forming MS plaques; and that death of the oligodendrocyte/myelin complex is the first in a uniform sequence of events that underpins active lesion pathology in typical relapsing disease. This hypothesis is illustrated in Figure 1. An alternative explanation for the proximity of active phagocytic and prephagocytic pathologies is that the latter is a secondary phenomenon. While consistent with the conventional paradigm of MS pathogenesis, the low prephagocytic/phagocytic lesion ratio in individual patients with early relapsing MS weakens this interpretation.

The factors that trigger oligodendrocyte apoptosis in newly forming MS lesions are speculative, and have been reviewed in detail elsewhere.[34] There is circumstantial evidence supporting the role of microglia-derived proinflammatory cytokines;[35] and comparison with the pathological changes observed in white matter ischaemia implicates oxidative stress and excitotoxicity as potential patho-mechanisms.[36] Whilst these factors may constitute 'pieces' of the molecular puzzle, they are also general accompaniments of microglial/macrophage activity and do not constitute a framework for the aetiology of MS. A foreign antigen that induces both oligodendrocyte injury and inflammatory cell recruitment would obviate the need to identify an auto-antigen in MS and has re-emerged as a serious aetiological candidate. The epidemiological data supporting a specific viral cause of MS have been recently reviewed by Lipton *et al.*[37]

Implications for Therapy

Current immunomodulatory and immunosuppressive therapies for relapsing MS are only partially effective. They primarily target the adaptive immune response, although undoubtedly also have downstream effects on the cytokine milieu and local immunity within the CNS. Convincing evidence that a Th1-mediated immune response can affect tissue damage in MS has emerged from recent clinical trials of natalizumab, a monoclonal antibody which inhibits alpha-4 integrin-mediated lymphocyte trafficking into the CNS, significantly reducing clinical and radiological relapses.[38–40] More recently, Phase II trials of alemtuzumab, a monoclonal anti-CD52 antibody that induces long-term T-cell depletion, have shown dramatic improvements in relapse rate and the risk of acquiring permanent disability relative to standard therapy with subcutaneous interferon beta 1-a.[41] These data suggest that amplification of tissue injury in early relapsing MS is chiefly mediated by the recruitment of a systemic immune response (Figure 1) and emphasize the imperative to commence such therapies in the early phases of the disease. Prephagocytic events are, however, not likely to be targeted by such an approach and the combination of immunomodulatory/immunosuppressive therapies with agents that promote oligodendrocyte integrity may be a superior therapeutic strategy, particularly in early relapsing disease when prephagocytic and active

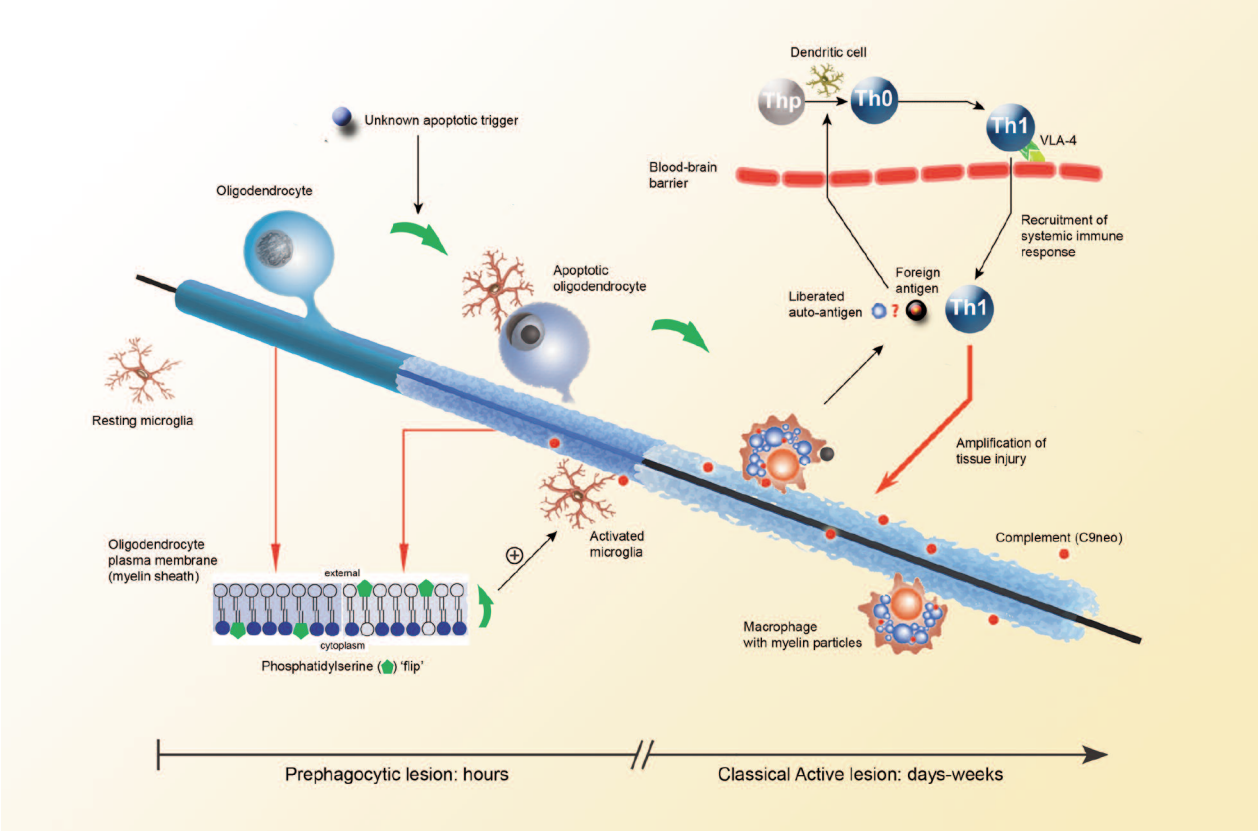

Figure 1. Temporal evolution of the newly forming MS lesion: a hypothesis. An as yet unidentified factor results in oligodendrocyte apoptosis and direct or secondary microglial activation. Programmed cell death is accompanied by the expression of phagocytic ligands on the abluminal surface of oligodendrocytes and their extended plasma membranes, the myelin sheath. Macrophages, primarily derived from local microglia, phagocytose apoptotic oligodendrocytes and degenerating myelin sheaths, a process that characterizes the classic active MS lesion and is usually complete within 2–3 weeks. A population of myeloid-like dendritic cells, possibly derived from CCR7+ microglia, migrates to the cervical lymph nodes and activates naïve T-lymphocytes to a memory/effector phenotype. These Th1 lymphocytes re-enter the central nervous system and are reactivated by antigen-presenting cells, possibly those located in Virchow-Robin spaces within the lesion. The recruitment of additional systemic immune populations dramatically amplifies the inflammatory process and local tissue injury. The antigen specificity of the T-lymphocyte response is unknown and may be directed toward a constitutive autoantigen, an autoantigen liberated by the apoptotic process, or epitopes derived from the unknown factor that also causes oligodendrocyte apoptosis

lesion load is maximal. Neuroprotection has already been proposed as a potential mode of action for both traditional therapies such as glatiramer acetate[42] and novel oral agents, such as fingolimod, that have shown promising results in Phase II trials in relapsing MS.[33] Enhancing oligodendrocyte survival with neurotrophic cytokines such as leukaemia inhibitory factor[43] and ciliary neurotrophic factor[44] has also been shown to have a therapeutic effect in animal models for MS.

In the hypothesis presented in Figure 1, the development of nascent MS lesions is uniform and the application of vastly different therapies for specific patient subgroups with clinically indistinguishable relapsing syndromes is irrelevant. While we believe that the evidence weighs in favour of this hypothesis, we

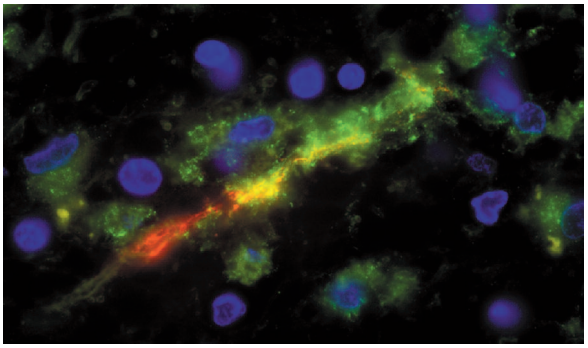

Figure 2. Upregulation of MHC 2 (green) in activated microglia clustered around C3d+ material (red) associated with a short segment of an axon in periplaque MS tissue. This tissue alteration may constitute a specific biomarker for MS which is not observed in other inflammatory and non-inflammatory white matter diseases

recognize that genetic factors are also likely to modulate the development of MS lesions, and response to specific therapies, in a given individual. However, research directed toward the determination of surrogate markers for MS pathological subtypes, as defined by Lucchinetti *et al.*,[21] may be based on flawed assumptions.

The MS Antigen: the 'Holy Grail' of MS Research?

The development of more effective targeted therapy has been hindered by the lack of a known MS-specific antigen, an incomplete understanding of the pathogenic sequences that take place in evolving and expanding MS lesions and inadequate animal models. Attempts to delineate the location and identity of the putative MS antigen have failed to discover a consistent target of oligospecific CSF immunglobulins, despite their remarkable temporal and clonal invariance. Antibodies directed against components of myelin also do not correspond with the major electrophoretic oligoclonal bands with any consistency, and are often of low affinity.[45,46] Similarly, we have recently shown that binding of immunoglobulin and complement to degenerating myelin sheaths is not a specific feature of MS, but is common to many diseases that affect white matter, including ischaemic stroke.[25] In this study, disease-specific deposits of IgG or activated complement that correlated with the known distribution of either foreign antigen or autoantigen, were detected in virus-infected cells in progressive multifocal leucoencephalopathy, subacute sclerosing panencephalitis and cytomegalovirus encephalitis; in glial limiting membranes in neuromyelitis optica; and in senile plaques in Alzheimer's dementia. In MS, specific immunostaining was restricted to short linear deposits of activated complement (C3d) on partly demyelinated axons located within unusual microglial nodules in normal-appearing periplaque white matter (Figure 2). These lesions may therefore indicate the site of an MS-specific target of innate or acquired immunity and therefore constitute a specific biomarker of the disease with pathogenetic significance.

In a recent study by Han *et al.*,[47] molecular profiling of MS and control tissue utilizing a proteomics approach yielded several proteins unique to chronic active MS plaques, including the molecules associated with coagulation, tissue factor and protein C inhibitor. Previously unsuspected in the pathogenesis of MS, dysregulation of coagulation was further explored by administration of hirudin and recombinant activated protein C to SJL/J mice with EAE, resulting in amelioration of the disease. Whilst the nature of the putative MS antigen was not established, this important paper validates a new methodology utilizing human tissue that may lead to the identification of candidate proteins important to disease pathogenesis and the discovery of targeted therapies. The directed application of proteomics to prephagocytic tissue in nascent lesions or periplaque white matter containing MS-specific microglial nodules, rather than the contents of already-established plaques, is perhaps more likely to yield information relevant to the pathogenesis of the disease, but is limited by the availability of suitable tissue.

Conclusions

MS presents with a readily identifiable clinical syndrome and, in the vast majority of cases, characteristic MR imaging and laboratory features. The neuropathology of early relapsing MS is unmistakable and variation in acute lesion pathology is largely accounted for by lesion stage, rather than heterogenous disease aetiologies amongst patients with indistinguishable clinical syndromes. Examination of newly forming, prephagocytic lesions suggests that oligodendrocyte death underpins the subsequent events that manifest pathologically as active demyelination; and that macrophage activity, widely held to be driven by a Th1 lymphocyte-mediated immune response toward a myelin antigen, is largely a scavenger response determined by the expression of phagocytic ligands on the plasma membranes of dying oligodendrocytes. While the events that occur within newly forming plaque in a given individual may be modulated by genetic or perhaps environmental factors, we propose that the overall mechanism of lesion formation is uniform in patients with relapsing MS. Therapies that target only the recruitment of a systemic immune response are therefore likely to be partially effective, and neuroprotective strategies are also required. Present animal models inadequately reflect the pathogenesis of MS, and the application of

emerging technologies such as proteomics to human tissue is more likely to yield useful pathogenetic information and lead to the discovery of targeted, more effective therapies.

Conflicts of Interest

No conflicts of interest were declared in relation to this article.

Address for Correspondence

Michael Barnett, Level 4, Brain and Mind Research Institute, 94 Mallett Street, Camperdown, New South Wales 2050, Australia
Phone: +61 2 93510730
Fax: +61 2 93510653
E-mail: mbarnett@mail.usyd.edu.au

Received: 20 August 2008
Accepted: 24 February 2009

References

1. Carswell R: *Pathological Anatomy: Illustrations of the Elementary Forms of Disease.* London: Orme, Brown, Green and Longman, 1838.
2. Brex PA, Ciccarelli O, O'Riordan JI, Sailer M, Thompson AJ, Miller DH. A longitudinal study of abnormalities on MRI and disability from multiple sclerosis. *N Engl J Med* 2002; **346:** 158–164.
3. Kostulas VK, Link H, Lefvert AK. Oligoclonal IgG bands in cerebrospinal fluid. Principles for demonstration and interpretation based on findings in 1114 neurological patients. *Arch Neurol* 1987; **44:** 1041–1044.
4. Rudick RA, Cookfair DL, Simonian NA, Ransohoff RM, Richert JR, Jacobs LD *et al.* Cerebrospinal fluid abnormalities in a phase III trial of Avonex (IFNbeta-1a) for relapsing multiple sclerosis. The Multiple Sclerosis Collaborative Research Group. *J Neuroimmunol* 1999; **93:** 8–14.
5. Lennon VA, Wingerchuk DM, Kryzer TJ , Pittock SJ, Lucchinetti CF, Fujihara K *et al.* A serum autoantibody marker of neuromyelitis optica: distinction from multiple sclerosis. *Lancet* 2004; **364:** 2106–2112.
6. Lennon VA, Kryzer TJ, Pittock SJ, Verkman AS, Hinson SR. IgG marker of optic-spinal multiple sclerosis binds to the aquaporin-4 water channel. *J Exp Med* 2005; **202:** 473–477.
7. Prineas JW, McDonald WI, Franklin RJM: Demyelinating Diseases. In: *Greenfield's Neuropathology*, 7th edn (Graham DI, Lantos PL, eds). London: Arnold 2002; pp471–550.
8. Prineas JW, Raine CS. Electron microscopy and immunoperoxidase studies of early multiple sclerosis lesions. *Neurology* 1976; **26:** 29–32.
9. Prineas JW, Kwon EE, Goldenberg PZ, Ilyas AA, Quarles RH, Benjamins JA *et al.* Multiple sclerosis. Oligodendrocyte proliferation and differentiation in fresh lesions. *Lab Invest* 1989; **61:** 489–503.
10. Navikas V, Link H. Review: cytokines and the pathogenesis of multiple sclerosis. *J Neurosci Res* 1996; **45:** 322–333.
11. Cannella B, Raine CS. The adhesion molecule and cytokine profile of multiple sclerosis lesions. *Ann Neurol* 1995; **37:** 424–435.
12. Merrill JE. Proinflammatory and antiinflammatory cytokines in multiple sclerosis and central nervous system acquired immunodeficiency syndrome. *J Immunother* 1992; **12:** 167–170.
13. Prineas JW, Graham JS. Multiple sclerosis: capping of surface immunoglobulin G on macrophages engaged in myelin breakdown. *Ann Neurol* 1981; **10:** 149–158.
14. Lucchinetti CF, Bruck W, Rodriguez M, Lassmann H. Distinct patterns of multiple sclerosis pathology indicates heterogeneity on pathogenesis. *Brain Pathol* 1996; **6:** 259–274.
15. Storch MK, Piddlesden S, Haltia M, Iivanainen M, Morgan P, Lassmann H. Multiple sclerosis: in situ evidence for antibody- and complement-mediated demyelination. *Ann Neurol* 1998; **43:** 465–471.
16. Hauser SL, Waubant E, Arnold DL, Vollmer T, Antel J, Fox RJ *et al.* B-cell depletion with rituximab in relapsing-remitting multiple sclerosis. *N Engl J Med* 2008; **358:** 676–688.
17. Storch MK, Stefferl A, Brehm U, Weissert R, Wallström E, Kerschensteiner M *et al.* Autoimmunity to myelin oligodendrocyte glycoprotein in rats mimics the spectrum of multiple sclerosis pathology. *Brain Pathol* 1998; **8:** 681–694.
18. Barnett MH, Prineas JW. Relapsing and remitting multiple sclerosis: pathology of the newly forming lesion. *Ann Neurol* 2004; **55:** 458–468.
19. Babbe H, Roers A, Waisman A, Lassmann H, Goebels N, Hohlfeld R *et al.* Clonal expansions of CD8(+) T cells dominate the T cell infiltrate in active multiple sclerosis lesions as shown by micromanipulation and single cell polymerase chain reaction. *J Exp Med* 2000; **192:** 393–404.
20. Gay FW, Drye TJ, Dick GW, Esiri MM. The application of multifactorial cluster analysis in the staging of plaques in early multiple sclerosis. Identification and characterization of the primary demyelinating lesion. *Brain* 1997; **120**(Pt 8): 1461–1483.
21. Lucchinetti C, Bruck W, Parisi J, Scheithauer B, Rodriguez M, Lassmann H. Heterogeneity of multiple sclerosis lesions: implications for the pathogenesis of demyelination. *Ann Neurol* 2000; **47:** 707–717.
22. Stadelmann C, Ludwin S, Tabira T, Guseo A, Lucchinetti CF, Leel-Ossy L *et al.* Tissue preconditioning may explain concentric lesions in Balo's type of multiple sclerosis. *Brain* 2005; **128:** 979–987.
23. Keegan M, König F, McClelland R, Brück W, Morales Y, Bitsch A *et al.* Relation between humoral pathological changes in multiple sclerosis and response to therapeutic plasma exchange. *Lancet* 2005; **366:** 579–582.
24. Lassmann H, Bruck W, Lucchinetti C. Heterogeneity of multiple sclerosis pathogenesis: implications for diagnosis and therapy. *Trends Mol Med* 2001; **7:** 115-121.
25. Barnett MH, Parratt JDE, Cho ES, Prineas JW. Immunoglobulins and complement in post-mortem multiple sclerosis tissue. Ann *Neurol* 2009; **65:** 32–46.
26. Breij EC, Brink BP, Veerhuis R, van den Berg C, Vloet R, Yan R *et al.* Homogeneity of active demyelinating lesions in established multiple sclerosis. *Ann Neurol* 2008; **63:** 16–25.
27. Barnett MH, Sutton I. The pathology of multiple sclerosis: a paradigm shift. Curr Opin *Neurol* 2006; **19:** 242–247.
28. Kivisäkk P, Mahad DJ, Callahan MK, Sikora K, Trebst C, Tucky B *et al.* Expression of CCR7 in multiple sclerosis: implications for CNS immunity. *Ann Neurol* 2004; **55:** 627–638.
29. de Vos AF, van Meurs M, Brok HP, Boven LA, Hintzen RO, van der Valk P *et al.* Transfer of central nervous system autoantigens and presentation in secondary lymphoid organs. *J Immunol* 2002; **169:** 5415–5423.
30. Fabriek BO, Zwemmer JN, Teunissen CE, Dijkstra CD, Polman CH, Laman JD *et al.* In vivo detection of myelin proteins in cervical lymph nodes of MS patients using ultrasound-guided fine-needle aspiration cytology. *J Neuroimmunol* 2005; **161:** 190–194.
31. Fischer HG, Reichmann G. Brain dendritic cells and macrophages/microglia in central nervous system inflammation. *J Immunol* 2001; **166:** 2717–2726.
32. Kappos L, Antel J, Comi G *et al.* Oral fingolimod (FTY720) for relapsing multiple sclerosis. *N Engl J Med* 2006; **355:** 1124–1140.
33. Dev KK, Mullershausen F, Mattes H, Kuhn RR, Bilbe G, Hover D *et al.* Brain sphingosine-1-phosphate receptors: implication for FTY720 in the treatment of multiple sclerosis. *Pharmacol Ther* 2008; **117:** 77–93.
34. Barnett MH, Henderson APD, Prineas JW. The macrophage in MS: just a scavenger after all? Pathology and pathogenesis of the acute MS lesion. *Mult Scler* 2006; **12:** 121–132.
35. Zajicek JP, Wing M, Scolding NJ, Compston DA. Interactions between oligodendrocytes and microglia. A major role for complement and tumour necrosis factor in oligodendrocyte adherence and killing. *Brain* 1992; **115**(Pt 6): 1611–1631.
36. Lassmann H. Hypoxia-like tissue injury as a component of multiple sclerosis lesions. *J Neurol Sci* 2003; **206:** 187–191.
37. Lipton HL, Liang Z, Hertzler S, Son KN. A specific viral cause of multiple sclerosis: one virus, one disease. *Ann Neurol* 2007; **61:** 514–523.

38. Dalton CM, Miszkiel KA, Barker GJ, MacManus DG, Pepple TI, Panzara M *et al.* Effect of natalizumab on conversion of gadolinium enhancing lesions to T1 hypointense lesions in relapsing multiple sclerosis. *J Neurol* 2004; **251:** 407–413.
39. Miller DH, Khan OA, Sheremata WA , Blumhardt LD, Rice GP, Libonati MA *et al.* A controlled trial of natalizumab for relapsing multiple sclerosis. *N Engl J Med* 2003; **348:** 15–23.
40. Tubridy N, Behan PO, Capildeo R, Chaudhuri A, Forbes R, Hawkins CP *et al.* The effect of anti-alpha4 integrin antibody on brain lesion activity in MS. The UK Antegren Study Group. *Neurology* 1999; **53:** 466–472.
41. Jones JL, Coles AJ. Campath-1H treatment of multiple sclerosis. *Neurodegener Dis* 2008; **5:** 27–31.
42. Ziemssen T, Kümpfel T, Klinkert WE, Neuhaus O, Hohlfeld R. Glatiramer acetate-specific T-helper 1- and 2-type cell lines produce BDNF: implications for multiple sclerosis therapy. Brain-derived neurotrophic factor. *Brain* 2002; **125**(Pt 11): 2381–2391.
43. Butzkueven H, Zhang JG, Soilu-Hanninen M, Hochrein H, Chionh F, Shipham KA *et al.* LIF receptor signaling limits immune-mediated demyelination by enhancing oligodendrocyte survival. *Nat Med* 2002; **8:** 613–619.
44. Linker RA, Maurer M, Gaupp S, Martini R, Holtmann B, Giess R *et al.* CNTF is a major protective factor in demyelinating CNS disease: a neurotrophic cytokine as modulator in neuroinflammation. *Nat Med* 2002; **8:** 620–624.
45. Cruz M, Olsson T, Ernerudh J Höjeberg B, Link H. Immunoblot detection of oligoclonal anti-myelin basic protein IgG antibodies in cerebrospinal fluid in multiple sclerosis. *Neurology* 1987; **37:** 1515–1519.
46. O'Connor KC, Chitnis T, Griffin DE, Piyasirisilp S, Bar-Or A, Khoury S *et al.* Myelin basic protein-reactive autoantibodies in the serum and cerebrospinal fluid of multiple sclerosis patients are characterized by low-affinity interactions. *J Neuroimmunol* 2003; **136:** 140–148.
47. Han MH, Hwang SI, Roy DB, Lundgren DH, Price JV, Ousman SS *et al.* Proteomic analysis of active multiple sclerosis lesions reveals therapeutic targets. *Nature* 2008; **451:** 1076–1081.